



“Clinical Presentation, Incidence and Types of Roux-En-Y Hepaticojejunostomy versus Hepaticoduodenostomy after Excision of Choledochal Cyst: A Randomized Clinical Trial and Experience”

Laz M A^{1*}, Ishad KY², Hossain M M³, Jafor MA⁴, Alam M M⁵, Hai AHMA⁶, Islam M N⁷

¹Assistant Professor, Department of Pediatric Surgery, Sir Salimullah Medical College, Dhaka, Bangladesh

²Resident Surgeon, Pediatric Surgery, Sir Salimullah Medical College & Mitford Hospital, Dhaka, Bangladesh

³Consultant (Pediatrician), Wangdue Hospital, Wangdue, Bhutan

⁴Professor & Head of Department, Pediatric Surgery, Sir Salimullah Medical College, Dhaka, Bangladesh

⁵Assistant Professor, Department of Pediatric Surgery, Cumilla Medical College, Cumilla, Bangladesh

⁶Assistant Registrar, Dept of Pediatric Surgery, Sir Salimullah Medical College & Mitford Hospital, Dhaka, Bangladesh

⁷Consultant, Department of Pediatric Surgery, Bangabandhu Sheikh Mujib Medical University, Dhaka, Bangladesh

*Corresponding Author

Mafia Afshin Laz

Article History

Received: 05.07.2021

Accepted: 02.08.2021

Published: 18.08.2021

Abstract: Introduction: Choledochal cyst (CC) is a rare congenital malformation of biliary tract. There occurs pathological dilatation of extrahepatic and/or intrahepatic biliary tree. About 85% of cases are reported below 15 years of age. Excision of choledochal cyst is required to relieve biliary obstruction thereby protecting the liver and pancreas as well as to prevent malignancy in long term. But controversy persists in the two existing techniques of biliary reconstruction after cyst excision. **Objective:** To analyze the clinical presentation, incidence and types of choledochal cyst and our experience in management of these congenital anomalies and compare the advantages and disadvantages between two modalities of biliary reconstruction. **Methods:** A prospective, controlled, clinical trial was conducted on patients with choledochal cyst in the Department of Pediatric Surgery, Sir Salimullah Medical College & Mitford Hospital, Dhaka, Bangladesh. They were divided into two groups; Group-A: Patients in whom biliary reconstruction was done by Roux-en-Y hepaticojejunostomy, Group-B: Biliary reconstruction done by Hepaticoduodenostomy. The two groups were compared in respect to clinical course, types of cyst, surgical difficulties with special emphasis on operating time, postoperative complications. **Results:** Choledochal cysts accounted for 0.79% of total admissions at our institute. Out of 31 admitted cases, 22 cases were enrolled in the study. The number of patients in group A was 10 and in group B were 12. Abdominal pain was the commonest presenting feature and Type I choledochal cyst was the most common finding. The average duration of surgery was less in group B (1 hour 25 min) than in group a (2 hours and 10 min). **Conclusion:** Biliary reconstruction by Hepaticoduodenostomy takes significantly less operative time than Roux-en-Y hepaticojejunostomy ($p < 0.05$) and needs single anastomosis. It is more anatomical, physiological, and easy to perform and associated with fewer complications.

Keywords: Anomalous pancreaticobiliary junction, Cholangitis, Choledochal cyst, Hepaticoduodenostomy, Roux-en-Y hepaticojejunostomy.

Copyright © 2021 The Author(s): This is an open-access article distributed under the terms of the Creative Commons Attribution 4.0 International License (CC BY-NC 4.0) which permits unrestricted use, distribution, and reproduction in any medium for non-commercial use provided the original author and source are credited.

I. INTRODUCTION

Choledochal cyst (CC) is a rare congenital malformation of biliary tract and occurs pathological dilatation of extrahepatic and/or intrahepatic biliary tree [1-3]. About 85% of cases are reported below 15 years of age [4]. Todani's classification system containing 5 types of CC is widely accepted at present [5]. Type I consists of saccular or fusiform dilatation of common bile duct (CBD) and type II represents a diverticulum of CBD. Type III, also known as choledochocele is described as dilatation of the intraduodenal portion of CBD. Type IVA represents multiple extrahepatic and intrahepatic cysts, but type IVB shows only extrahepatic cysts. Type V, termed as Caroli's disease involves intrahepatic bile duct cysts. Lilly *et al.* described a variant called *Forme fruste* CC, in which the child presents with symptoms of CC and there is anomalous pancreaticobiliary junction (APBJ) without dilatation of biliary ducts [6]. It is non-invasive and not associated with radiation exposure seen in CT scan. The diagnostic accuracy of MRCP for CC is 90- 100% and is the gold standard for diagnosis [4, 7]. Management of CC is developed over the years from simple drainage procedure to complete resection of cyst and biliary tract reconstruction. Infants with CC usually present with jaundice and abdominal lump. Abdominal pain is the most common presentation in older children and adolescents [4, 7]. Ultrasonography as the initial diagnostic method has a sensitivity of 71 to 97% [4, 8]. Contrast enhanced computed tomography (CECT) is a useful imaging method, but MRCP (magnetic resonance cholangiopancreatography) is the diagnostic modality of choice. It accurately visualizes the cyst and ductal structures and reasonably detects APBJ. Excision of CC is essential to protect the liver, pancreas and prevent development of bile duct and gall bladder cancer [8, 9]. The outcome of CC is improved and the long term complications are diminished, but the controversy revolves around biliary reconstruction after excision of the cyst. There are two common modes of reconstruction; Roux-en-Y hepaticojejunostomy (RYHJ) and Hepaticoduodenostomy (HD). Both the procedures carry their inherent problem and surgeons publish their individual preferences [1, 10, 11]. The report highlights the experience in the managing pediatric CCs in our population. The advantages and disadvantages of two modalities of surgery are compared.

II. MATERIALS AND METHODS

This is a prospective study conducted from Jun 2013 to July 2021 in the department of pediatric surgery, Sir Salimullah Medical College & Mitford

Hospital, Dhaka, Bangladesh. Patients with choledochal cyst admitted for surgery were enrolled for study. All the patients were subjected to detailed history and thorough clinical examination. Routine hematological investigations like hemogram, liver function test (LFT), coagulation profile and renal function test were performed. Abdominal ultrasonography was done in all patients to evaluate biliary system; the type of choledochal cyst, size, contour of proximal ducts, vascular anomaly and hepatic echotexture. CECT was performed in five cases. MRCP was done in 15 patients with choledochal cyst to reveal exact nature of biliary system, pancreaticobiliary common channel and pancreatic duct. The exclusion criteria were as follows:

- a) Age: >14 years and <3 months.
- b) Types of choledochal cyst: Type-III (choledochocele), Caroli's disease and 'Forme Fruste' choledochal cyst.
- c) Choledochal cyst with cholangitis features.
- d) Choledochal cyst with associated anomalies like cardiac and renal.
- e) Patients unfit for surgery and severe malnutrition.

The parents were fully explained about the nature of the disease, operative procedure, possible complications and consent for treatment was obtained. Patients were operated on general anesthesia by right sub costal incision. Excision of CC and biliary reconstruction was done in all cases. They were assigned into two groups by simple randomization; Group-A: Biliary reconstruction done by Roux-en-Y hepaticojejunostomy, Group-B: Biliary reconstruction done by hepaticoduodenostomy. The two groups were comparable with respect to age at presentation, sex, type of choledochal cyst and clinical features. The parameters used to compare the results in two groups were operative time, surgical difficulties, postoperative leak, pain, cholangitis and gastritis, duration of hospitalization, morbidity and mortality. Regular follow up was done in OPD along with ultrasonography and LFT. Complaints of the patient and complications after surgery were recorded.

III. RESULTS

During the above period thirty-one cases of choledochal cysts were admitted to the department of pediatric surgery. Twenty-two cases were enrolled in the study after exclusion criteria. There were 11 male children and 11 female children in this study, the sex ratio being 1:1. The median age at presentation was 5 years. Eleven patients were below 5 years of age and 11 were above 5 years.

Total number of patients in group A was 10 and in group B were 12. The mean age at presentation in group A was 5.4 years and in group B was 4.8 years. Abdominal pain was the commonest presenting feature followed by jaundice and lump abdomen (Table-1). The classic triad of pain, lump and jaundice was seen in 22.7% of our cases. Ultrasonography was done in all cases for diagnosis. MRCP was done in 70% of cases in group A and 85% of cases in group B (Figure-1). CECT abdomen was done in 20% of cases in group A and 25% of cases in

group B. Due to poor financial condition both MRCP and CECT could not be done in 2 cases, one from each group. Type I choledochal cyst was the most common finding seen in 77.27% of cases (Figure-2a, b). It is followed by Type IVB and Type IVA, but Type II cyst was not detected in this study group. The average operative time was 2hr 10 min in group A and 1hr 25 min in group B. The operative time was shorter by 55 min (64.7% less time) in HD group as compared to RYHJ group (Figure-3).

Table-1: Clinical presentation of study population (N=31)

	Group A(RYHJ) (n = 10)	Group B (HD) (n = 12)
Abdominal pain	8	9
Jaundice	4	5
Lump	2	3
Classical triad	2	3

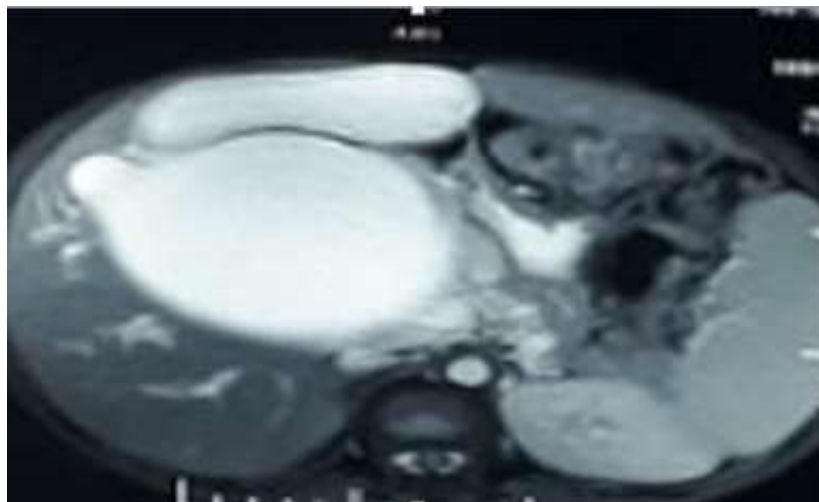


Fig-1: MRCP picture showing gross saccular choledochal cyst, Type I.

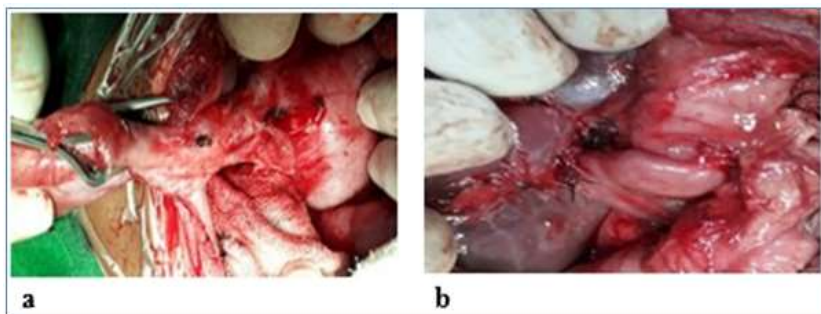


Fig-2(a): Intraoperative photograph showing Type 1 choledochal cyst (b) Hepaticoduodenostomy after cyst excision

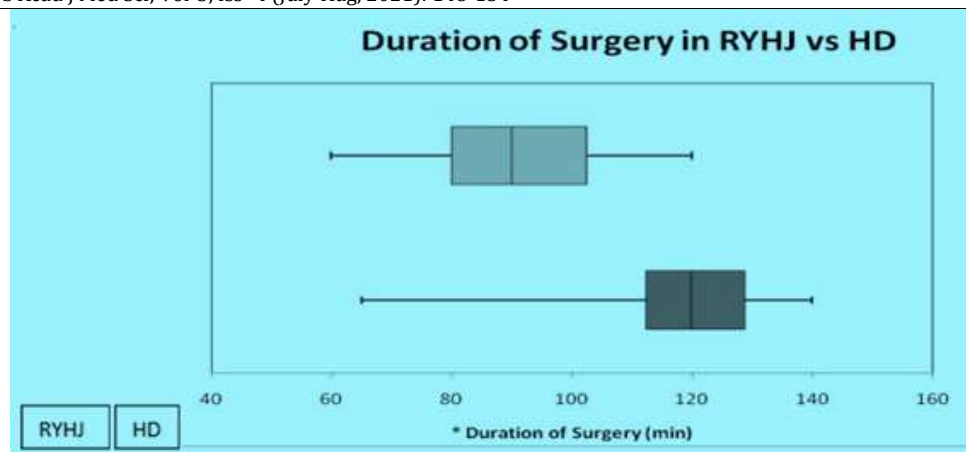


Fig-3: Box plot graph comparing operating time, RYHJ vs HD (t=3.01, *p=0.006).

Table-2: Early Postoperative Complications (during hospital stay) (N=31)

Complications	Group A (n=10)	Group B (n=12)	p-value
Postoperative pain	4	2	0.34
Anastomotic leak	1	1	1.0
Early cholangitis	2	2	1.0
Total	7	5	0.23

Table-3: Postoperative Complications (during 1 year follow up) (N=31)

Complications	Group A (n=10)	Group B (n=12)	p-value
Gastritis	2	3	1.0
Cholangitis	2	2	1.0
Pancreatitis	1	1	1.0
Intestinal Obstruction due to Adhesion	1	0	0.45
Intrahepatic Stone Formation	2	1	0.57
Total	8	7	0.38

In early postoperative period pain, anastomotic leak and features of cholangitis were seen more commonly in group A patients (Table-2). Bilious RT aspirate was seen up to 4 days postoperatively in group A and the average time to start oral feeds was 6 days. RT aspirate was bilious up to 3 days on an average in group B patients and the feeding was started on 4 days after surgery. Mean duration of hospitalization was 9 days in both the groups and there was no mortality in any group. During 1 year follow up period reflux gastritis was seen in 20% of cases of group A and 25% of cases in group B (Table-3). Cholangitis was seen in 20% of cases in group A and 16.6% of cases in group B. Postoperative adhesive intestinal obstruction was seen in one case in group A. It was managed conservatively in our hospital. Intrahepatic stone formation was seen in two cases in group A and one case in group B. None of our patients had anastomotic stricture or malignancy on follow up.

IV. DISCUSSION

The incidence of CC estimated in western population is 1 in 100/150 000 live births [8, 12, 13] and it is more common in Asian countries especially in Japan [14,15,16]. Several theories are proposed for etiology of CC. Babbitt's common channel theory is widely accepted [17]. The resultant mixture of biliary and pancreatic juice activates pancreatic enzymes, which further causes inflammation and dilatation of biliary duct wall. A long common channel is produced by the union of pancreatic duct and common bile duct outside the ampulla of Vater. Here the long common channel is arbitrarily defined and authors describe it as 10 mm to 45 mm [18, 19]. Forme Fruste CC supports this APBJ theory in pathogenesis and complications of CC. But APBJ is present in 50-80% of patients with CC [18]. Singham et al. described the dilation in CC to be due to overproduction of epithelial cells during cannulation phase of embryogenesis [19]. Davenport and Basu described a pathological paucity of neurons and

ganglions in CC [20]. They proposed that round cysts are congenital and aganglionosis causing distal obstruction is similar to Hirschsprungs disease. The female predominance of this disease is widely reported with female to male ratio of 3-4:1 [1, 4, 8]. But in the present study sex ratio is 1:1. The probable cause of fewer female enrolments could be attributed to less importance being given to female child. The present study shows that, abdominal pain is most common presentation (77.2%) followed by jaundice (40.9%) and abdominal lump (18.2%). Authors also suggest that fusiform dilations are due to acquired APB]. Pathophysiologically, 3 types of ABPJ have been described by Komi et al; (i) Right angled union- associated with cystic dilatation of CBD, (ii) Acute angled union- associated with fusiform dilatation of CBD and (iii) Right/ acute angled union with accessory pancreatic duct [21]. Abdominal pain was also the major presenting feature (86% cases) in series reported by Mukhopadhyay et al [22]. Jaundice and abdominal pain were also prominent features in the study by Silva-Baez et al accounting for 78.5% and 85.7% of cases respectively [1]. Type I variety is most common type accounting for about 90% of cysts and it is followed by type IV cysts in frequency [4, 8]. In the present series Type I accounted for 77.27% of cases and the remaining were type IV out of which type IVA was 4.45% and type IVB was 18.18% of cases. Mukhopadhyay et al. noticed type I cyst accounting for 79.7% and type IV cysts as 15% of their series [22]. The classic triad of abdominal pain, mass and jaundice is recorded in about 17 to 21.5% of cases [22, 23]. However, the triad was present in 22.7% of our cases. The types of cyst and age at presentation between the two groups in our series were statistically non-significant. Historically, internal drainage procedure (Cholecystoenterostomy) was the surgical approach for CC for decades. Currently this procedure is abandoned due to high risk of complications like cholangitis, pancreatitis and malignancy in up to 50% of cases [18, 24]. Two techniques of hepaticoenterostomy gained popularity; RYHJ and HD. Although appendix interpositioned hepaticoenterostomy was tried in some centers, it failed to be popular. The appendix underwent stenosis and there was biliary obstruction and development of hepatic fibrosis [24]. RYHD is reported to be the preferred method in many centers, but HD is still a simple and easy technique. We compared the advantages and disadvantages of both the procedures so as to opt for an ideal method of biliary reconstruction after excision of CC. The operative time and duration of anesthesia counts a lot for postoperative morbidity and mortality

especially in infants and young children. The average operating time was less in HD group (1 hour & 25 min) as compared to RYHJ group (2 hours & 10 min). This difference is statistically significant ($p=0.006$) and is the major advantage in HD group. Reoperation was needed in 70% of patients due to development of complications [25]. Therefore complete excision of CC became essential for surgical management. The complications were reduced dramatically along with a decreased incidence of malignancy (0.7%) [26]. Lilly's method of cyst excision is needed whenever intense pericyclic fibrosis precludes complete resection. The less adherent portion of cyst is removed and densely adherent part of cyst wall retained; the mucosal lining are stripped or ablated by diathermy [27]. The postoperative complications differ from institutions, age of the patient and in different surgical procedures. Anastomotic stricture is reported in 4.1% of cases following bilioenteric anastomosis for CC [28], but none of our patients have anastomotic stricture. It was due to the fact that, a wide anastomosis was performed between intestine and hilum of liver. In the present study biliary reflux gastritis was seen to be more marked in HD group (25%) than RYHJ group (20%), but it was not statistically significant. Shimotakahara et al. had also reported high incidence of duodenogastric bile reflux (33.3%) in HD patients and they preferred RYHJ for bilioenteric anastomosis [10]. Postoperative cholangitis and adhesive intestinal obstruction were observed more frequently in RYHJ group than HD group in our study. Adhesive bowel obstruction was found on follow up of one of our patients in RYHJ group (10%) and none in HD group. Shimotakahara et al. also found this complication in 7.1% of their series in RYHJ group and none in HD group [10]. Intrahepatic stone formation was seen 10 to 16.7% of children after cyst excision [25,29] and it was observed in 20% of our cases in group A and 8.3% of cases in group B. On comparison between two groups these postoperative complications were not statistically significant. In a recent meta- analysis, Narayanan et al. also found no significant difference in postoperative anastomotic leak, stenosis, cholangitis and adhesive bowel obstruction between HD and RYHJ biliary reconstruction after CC excision [30]. Although the average duration of hospital stay was equal in both of our groups, authors noted a shorter hospital stay in HD patients [1, 30]. The excision of CC significantly reduces the development of malignancy, but intrahepatic cholangiocarcinoma is observed on long term follow up [4]. None of our patients developed malignancy on follow up. Mortality after surgery for CC is reported in 1.27%

and 5.7% CC patients in series reported by Mukhopadhyaya et al. and Sharma et al. respectively [11,22]. The classical triad of presentation was recorded more frequently than other series. Surgeons still debate for decades regarding ideal surgical management of CC and the most common reconstructive technique following excision of Cyst is RYHJ [24]. Mukopadhyaya et al. described HD as a simple procedure preserving normal anatomy and physiology [22]. But Shimotakahara et al. did not recommend HD because of high incidence of duodenogastric biliary reflux and other complications [10]. They described RYHJ as their exclusive technique of choice. In this background, we have clearly defined the advantages of HD over RYHJ especially the duration of surgery, which is significantly less in HD group. Presently, HD is our technique of choice for biliary reconstruction after excision of CC. The mortality in the series reported by Mukhopadhyaya et al. was noted only in RYHJ group. Mortality was not observed in our series, but we observed morbidity of 25% of patients. Shimotakahara et al. and Todani et al. reported morbidity of 17.5% and 23.3% in their respective series [10, 31] without any mortality. This prospective study is a reflection of presentation of CCs in Bangladesh along with the management approach and short term follow up. The disease is known for typical female preponderance, but the sex ratio is equal in our study population.

V. CONCLUSION

Choledochal cyst is an uncommon disease for which resection of the cyst along with a wide bilioenteric anastomosis is essential for better outcome. Biliary reconstruction by HD takes significantly less operative time than RYHJ ($P < 0.05$) and needs single anastomosis. It is more anatomical, physiological, and easy to perform and associated with fewer complications as compared to RYHJ. A longer study is required to identify further complications in the current surgical practice and to detect development of malignancy.

REFERENCES

1. Silva-Baez, H., Coello-Ramírez, P., Ixtabalán-Escalante, E. M., Sotelo-Anaya, E., Gallo-Morales, M., Cordero-Estrada, E., ... & Ploneda-Valencia, C. F. (2016). Treatment of choledochal cyst in a pediatric population. A single institution experience of 15-years. Case series. *Annals of Medicine and Surgery*, 5, 81-85.
2. Thatipamula, A. B., & Moka, J. (2016). Surgical Management of Choledochal Cysts in Children-Our Experience in a District Level Teaching Hospital.
3. She, W. H., Chung, H. Y., Lan, L. C. L., Wong, K. K., Saing, H., & Tam, P. K. H. (2009). Management of choledochal cyst: 30 years of experience and results in a single center. *Journal of pediatric surgery*, 44(12), 2307-2311.
4. Tadokoro, H., & Takase, M. (2012). Recent advances in choledochal cysts.
5. Todani, T., Watanabe, Y., Narusue, M., Tabuchi, K., & Okajima, K. (1977). Congenital bile duct cysts: classification, operative procedures, and review of thirty-seven cases including cancer arising from choledochal cyst. *The American Journal of Surgery*, 134(2), 263-269.
6. Lilly, J. R., Stellin, G. P., & Karrer, F. M. (1985). *Forme fruste choledochal cyst*. *Journal of pediatric surgery*, 20(4), 449-451.
7. Holcomb, G. W., Murphy, J. P., & Ostlie, D. J. (2014). *Ashcraft's Pediatric surgery e-book*. Elsevier Health Sciences.
8. Gonzales, K.D., Lee, H. (2012). Choledochal Cyst. In: Coran AG, Adzick NS, Krummel TM, Laberge J, Shamberger RC, Caldmone AA. Editors. *Pediatric Surgery*. 7th ed. Elsevier Saunders, 1331-9.
9. Ono, S., Fumino, S., Shimadera, S., & Iwai, N. (2010). Long-term outcomes after hepaticojejunostomy for choledochal cyst: a 10- to 27-year follow-up. *Journal of pediatric surgery*, 45(2), 376-378.
10. Shimotakahara, A., Yamataka, A., Yanai, T., Kobayashi, H., Okazaki, T., Lane, G. J., & Miyano, T. (2005). Roux-en-Y hepaticojejunostomy or hepaticoduodenostomy for biliary reconstruction during the surgical treatment of choledochal cyst: which is better?. *Pediatric surgery international*, 21(1), 5-7.
11. Sharma, A., Pandey, A., Rawat, J., Ahmed, I., Wakhlu, A., & Kureel, S. N. (2011). Conventional and unconventional surgical modalities for choledochal cyst: Long-term follow-up. *Annals of Pediatric Surgery*, 7(1), 16-18.
12. Bhavsar, M. S., Vora, H. B., & Giriappa, V. H. (2012). Choledochal cysts: a review of literature. *Saudi journal of gastroenterology: official journal of the Saudi Gastroenterology Association*, 18(4), 230.
13. Howard, E.R. (1991). Choledochal cysts. In: Howard ER. Editor. *Surgery of liver disease in children*. Butterworth-Heinemann, Oxford, 78-90.
14. Lipsett, P.A., Pitt, H.A. (2003). Surgical treatment of choledochal cysts. *J Hepatobiliary Pancreat Surg*, 10(5):352-9.
15. Shi, L. B., Peng, S. Y., Meng, X. K., Peng, C. H., Liu, Y. B., Chen, X. P., ... & Chen, H. R. (2001). Diagnosis and treatment of congenital choledochal cyst: 20 years' experience in

- China. *World journal of gastroenterology*, 7(5), 732.
16. Miyano, T., Yamataka, A., & Li, L. (2000, November). Congenital biliary dilatation. In *Seminars in pediatric surgery* (Vol. 9, No. 4, pp. 187-195). WB Saunders.
 17. Babbitt, D. P. (1969). Congenital choledochal cyst: new etiological concept based on anomalous relationships of the common bile duct and pancreatic bulb. *Ann Radiol*, 12, 231-240.
 18. Jabłońska, B. (2012). Biliary cysts: etiology, diagnosis and management. *World journal of gastroenterology: WJG*, 18(35), 4801.
 19. Singham, J., Yoshida, E. M., & Scudamore, C. H. (2009). Choledochal cysts: part 1 of 3: classification and pathogenesis. *Canadian Journal of Surgery*, 52(5), 434.
 20. Davenport, M., & Basu, R. (2005). Under pressure: choledochal malformation manometry. *Journal of pediatric surgery*, 40(2), 331-335.
 21. Mukhopadhyay, B., Shukla, R. M., Mukhopadhyay, M., Mandal, K. C., Mukherjee, P. P., Roy, D., ... & Basu, K. S. (2011). Choledochal cyst: a review of 79 cases and the role of hepaticoduodenostomy. *Journal of Indian Association of Pediatric Surgeons*, 16(2), 54.
 22. Lipsett, P. A., Pitt, H. A., Colombani, P. M., Boitnott, J. K., & Cameron, J. L. (1994). Choledochal cyst disease. A changing pattern of presentation. *Annals of surgery*, 220(5), 644.
 23. Metcalfe, M. S., Wemyss-Holden, S. A., & Maddern, G. J. (2003). Management dilemmas with choledochal cysts. *Archives of Surgery*, 138(3), 333-339.
 24. Chijiwa, K., & Koga, A. (1993). Surgical management and long-term follow-up of patients with choledochal cysts. *The American journal of surgery*, 165(2), 238-242.
 25. Watanabe, Y., Toki, A., & Todani, T. (1999). Bile duct cancer developed after cyst excision for choledochal cyst. *Journal of hepato-biliary-pancreatic surgery*, 6(3), 207-212.
 26. Lilly, J.R. (1979). The surgical treatment of choledochal cyst. *Surg Gynecol Obstet*, 149(1):36-42.
 27. Hata, Y., Sasaki, F., Takahashi, H., Tamura, M., Ohkawa, Y., Saji, Y., ... & Uchino, J. (1993). Surgical treatment of congenital biliary dilatation associated with pancreaticobiliary maljunction. *Surgery, gynecology & obstetrics*, 176(6), 581-587.
 28. Yamataka, A., Ohshiro, K., Okada, Y., Hosoda, Y., Fujiwara, T., Kohno, S., ... & Miyano, T. (1997). Complications after cyst excision with hepaticoenterostomy for choledochal cysts and their surgical management in children versus adults. *Journal of pediatric surgery*, 32(7), 1097-1102.
 29. Narayanan, S. K., Chen, Y., Narasimhan, K. L., & Cohen, R. C. (2013). Hepaticoduodenostomy versus hepaticojejunostomy after resection of choledochal cyst: a systematic review and meta-analysis. *Journal of Pediatric Surgery*, 48(11), 2336-2342.
 30. Todani, T., Watanabe, Y., Mizuguchi, T., Fujii, T., & Toki, A. (1981). Hepaticoduodenostomy at the hepatic hilum after excision of choledochal cyst. *The American Journal of Surgery*, 142(5), 584-587.