



Case Report

Post-Operative Cerebellar Mutism in an Adolescent girl: A Case Report in Bangladesh

Fahmida Ferdous^{1*}, Hariprakash Chakravarty², Md Faruq Alam³, Md Mashukur Rahman Chisty⁴, Khandaker Parvez Ahmed⁵, Jinat Imtiaz Ali⁶, Syed Shahrier Rahman⁷

¹Assistant Professor, Department of Psychiatry, Z H Sikder Women's Medical College and Hospital, Dhaka, Bangladesh

²Chief Neurosurgeon, Department of Neuroscience, Z H Sikder Women's Medical College and Hospital, Dhaka, Bangladesh

³Professor and Director, National Institute of Mental Health (NIMH), Sher-E-Bangla Nagar, Dhaka, Bangladesh

⁴Senior Lecturer, Department of Anatomy, Dhaka National Medical College and Hospital, Dhaka, Bangladesh

⁵Consultant and Neurologist, Department of Neuroscience, Z H Sikder Women's Medical College, Dhaka, Bangladesh

⁶Professor and Director, International Institute of Mother Languages Dhaka, Bangladesh

⁷Professor, Department of Linguistics, University of Dhaka, Bangladesh

*Corresponding Author

Fahmida Ferdous

Article History

Received: 18.01.2020

Accepted: 09.02.2020

Published: 30.10.2020

Abstract: Introduction: The cerebellar mutism syndrome is a neurological condition which has been seen in children and only rarely described in adults after surgery of the posterior fossa. It usually appears as a consequence of posterior fossa surgery in children with cerebellar or fourth ventricle tumors. **Objectives:** It is a case report of an adolescent girl from Bangladesh presenting with postoperative cerebellar mutism. **Case:** The 15-year-old young, student initially presented with headache of raised intracranial pressure due to obstruction. She developed mutism on the second postoperative day following Surgery for astrocytoma of fourth ventricle. By the second and third post-operative day, her responses to query had almost stopped, but to persistent queries she gave a single word response and it was restricted to either 'yes' or 'no'. She remained silent and kept her eyes closed most of the time and cried for any attempts to wake her. She had mood instability with sudden unprovoked laughter followed by cry. She ate what she was fed and did not have any difficulty swallowing. **Conclusion:** To the authors' best knowledge, this is first case report of the cerebellar mutism in Bangladesh which would help the clinicians to deal with syndrome.

Keywords: Cerebellar Mutism, Posterior fossa syndrome, Bangladesh, Language and Speech impairment.

Copyright © 2020 The Author(s): This is an open-access article distributed under the terms of the Creative Commons Attribution 4.0 International License (CC BY-NC 4.0) which permits unrestricted use, distribution, and reproduction in any medium for non-commercial use provided the original author and source are credited.

INTRODUCTION

The cerebellar mutism syndrome (CMS) is a relatively uncommon neurological disorder considered for decrease speech after cerebellar lesion [1, 2]. The syndrome denotes the constellation of decrease speech, disturbances in balance i.e. ataxia, motor disturbances such as hypotonia and mood disturbances expressed as irritability following surgery for cerebellar or fourth ventricle growths in child(ren) and adolescent(s) [1-14]. The incidence of CMS after posterior fossa surgery in children has been reported to range between 8%-

39% in the recent literature [5, 7, 9]. CMS has been reported to affect approximately 25% of patients undergoing operations for medulloblastoma [4, 13]. A recent review among 257 children who developed CMS after surgery, 62.7% of the cases had a medulloblastoma, 24.9% has astrocytoma, 11.2% had ependymoma, 0.4% had meningioma, and 0.4% had germ cells tumor [11]. It has been used synonymously as posterior fossa syndrome (PFS) or as a part of wider PFS [2, 4, 6, 11]. CMS usually has been reported as a consequence of posterior fossa surgery in children with cerebellar or fourth

ventricle growths [1, 2, 5, 6, 8]. The reported mean age of CMS was 6-7 years, however, it has been reported in adults after surgery of the posterior fossa though it's rare [1, 12]. In adults, CMS has been found in about 1% as the incidence rate [1, 5]. Usually, CMS is preceded by a short postoperative period of 1-2 days of normal speech and resolves approximately 7 to 8 weeks later [2, 12, 13]. However, in some patients, recovery may be prolonged, and many are left with permanent disabling neurological sequelae [3, 4, 8, 13]. The causal pathophysiology of CMS is yet to be unveiled [1]. Previous researches revealed risk factors such as, brainstem involvement by the tumor, midline location and tumor type i.e. medulloblastoma, pre-operative language impairment, low socioeconomic level of the families, left-handedness, tumor size, neurosurgical techniques and approaches, radical resection and younger age at diagnosis [3]. Though it is a common pediatric neuro-oncological problem, this is the first case report of CMS from Bangladesh.

CASE REPORT

A 15-year-old young, unmarried, student, Muslim girl, with average intelligence level, hailing from urban background with lower economic upbringing presented to us with complaints of severe headache for the last 2 months. As per description of the respondent, headache aggravates as she wakes up from sleep and subsides after vomiting. She had history of nausea and recurrent episodes of vomiting, visual obscuration during headache and progressive blurring of vision over the last one month.

At presentation she was found to be thin and weak. Her speech and higher mental function were nearly normal with a Mini Mental State Examination (MMSE) score of 28. Fundus examination revealed established papilledema however her extraocular eye movements were normal. She had a mild bilateral lateral arm drift with a relative normal motor power. Cerebellar functions i.e. finger-nose test, heel-shin test, rapid alternating movement of hand were impaired. She had imbalance while walking and had impaired tandem walking.

Magnetic Resonance Imaging (MRI) of brain on T2WI revealed a heterogeneously hyper-intense mass situated in the fourth ventricle causing obstruction to CSF flow, leading to tri-ventricular hydrocephalus (Figure 1-3). Gadolinium contrast images showed patchy enhancement of the lesion with a size of 30mm in diameter. The tumour seemed to arise from the roof of the fourth ventricle with infiltration of the fourth ventricular floor. There was evidence of tonsillar herniation going up to the C1 arch.

As the patient had gross hydrocephalus with impending herniation an emergency right Ventriculoperitoneal shunt was done. She recovered well from the surgery. Computed Tomography (CT) scan of head showed adequate decompression of the ventricles with Ventricular tube in position. After 3 days she was taken up for tumour excision. Mid line suboccipital craniotomy and excision of C1 posterior arch was performed and midline tello-velar approach sort with excision of lower portion of Vermis. The tumour was mostly arising from the roof of the ventricle with-out any definitive margin. It was heterogenous in consistency, varying from firm outer capsule to soft inner core and moderately vascular with blood supply from branches of Posterior Inferior Cerebellar Artery (PICA). The tumour was removed piecemeal using ultrasonic aspirator. The tumour was removed sub-totally, as it was infiltrating the floor of the fourth ventricle; a thin layer of tumour was left over the brainstem. Following overnight ventilation, she was extubated. Post operatively CT scan of head showed adequate tumour removal (Figure 1-3).

During the immediate post-operative period the patient had dis-conjugate eye movements, and tends to keep her eye closed. She was responding to oral commands and gave fluent verbal response in short sentences for questions asked. Her spontaneous speech was minimal, with requests for food or water. She had appendicular in-coordination and her gait could not test.

By the second post-operative week she started to open eyes more often with her eye movements more conjugated. She had mood instability with sudden unprovoked laughter followed by cry. Psychiatrist and speech therapist were involved in her treatment.

By the second and third post-operative day, her responses to query had almost stopped, but to persistent queries she gave a single word response and it was restricted to either 'yes' or 'no'. She remained silent and kept her eyes closed most of the time and cried for any attempts to wake her. She ate what she was fed and did not have any difficulty swallowing. She was given perioperative steroids to prevent any retraction related oedema. Physiotherapy and speech therapy were continued as her mood stabilised.

The pathology was reported to be a WHO grade 1 Astrocytoma with no signs of pleomorphism and nuclear atypia. Now she is referred for speech and motor rehabilitation.

During her two months follow up, she was walking with minimal assistance. She could communicate her essential needs to her primary care giver, by two or three worded sentences. Eye position had come to near normal with conjugated movements.

Ethical issues were maintained accordingly and written informed consent is taken for publication of the report from the patient.

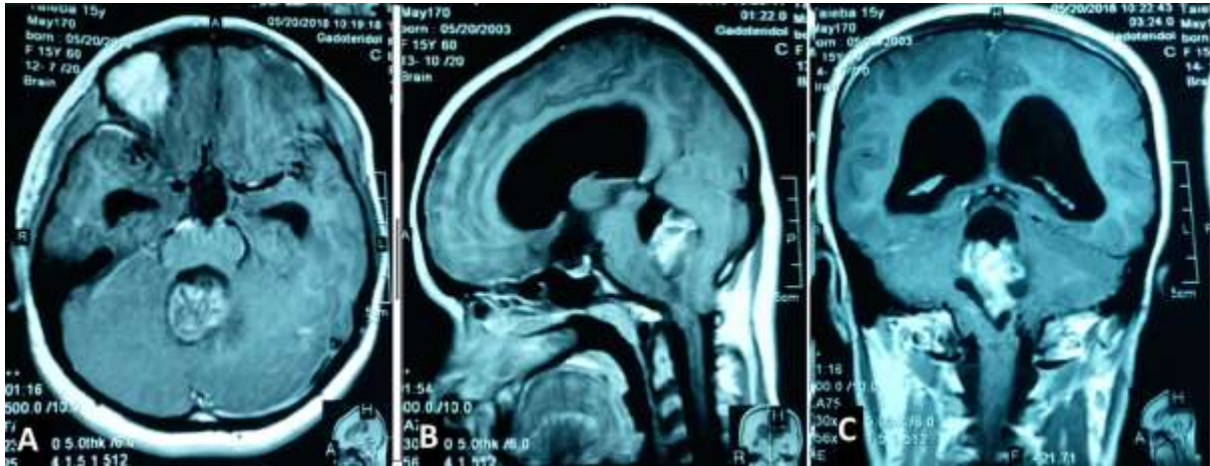


Fig-1: MRI BRAIN T1WI with Contrast shows a patchy enhancing lesion arising from the roof of the 4th ventricle with partial attachment to the brainstem near the fourth ventricular floor. Dilatation of the temporal horns & body of the lateral ventricle noticed

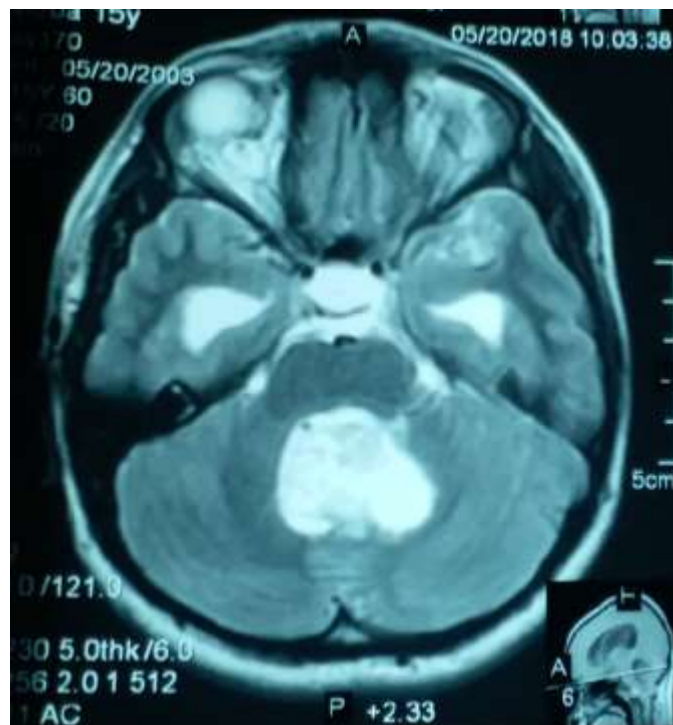


Fig-2: MRI T2WI shows a heterogeneously T2 hyperintense lesion involving the 4th ventricle

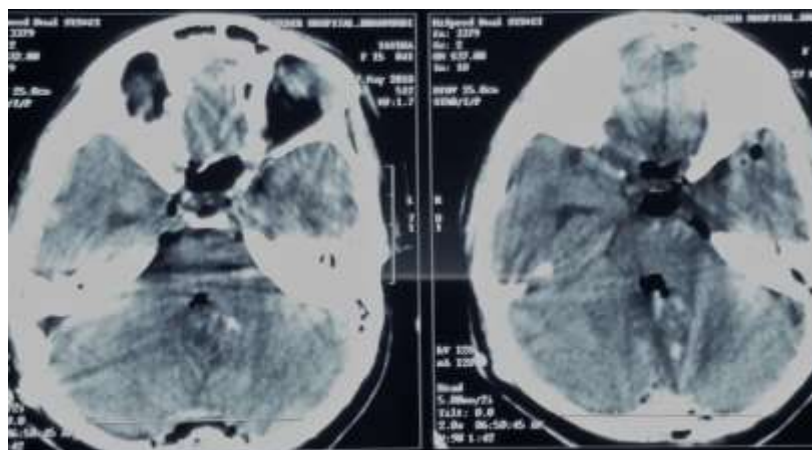


Fig-3: Post-operative CT brain shows near total excision of tumor with postoperative pneumo-cephalus

DISCUSSION

We aimed to report a case of CMS in Bangladesh. Our case was a 15-year-old girl from lower economic upbringing. Similar age distribution was also reported in other reports such as the syndrome was reported in 20 year old female after stroke [1], in 10 year old male [7], in 12 year old right handed male [11], in 33 year and 56 year old females [12]. However, a review reported the mean age of CMS was 6-7 years, and in adults it was rare after surgery of the posterior fossa [1, 12]. A case series of 6 cases also support the age distribution of 6 to 12 years, who developed cerebellar mutism after resection of posterior fossa mass as a result of posterior fossa trauma [15]. Another review of 32 children mentioned the age range as 3-13 years [10]. Symptoms of speech difficulties were noted on the second post-operative day with mood instability expressed by sudden unprovoked laughter followed by cry, and her responses to query had almost stopped, which followed the classical feature of CMS [1-6]. It was developed on the fifth postoperative day [7, 15], 1-2 days [15], on the post-operative day 1 [16]. However, usually, it develops after 1-2 days of normal speech and resolves approximately 7 to 8 weeks later [2, 12, 13]. The histopathological diagnosis of the reported case was Astrocytoma (WHO grade 1) with no signs of pleomorphism and nuclear atypia which supports the distribution of previous histopathological diagnoses [1-7]. Previous researches found the incidence was most common after the surgery of medulloblastoma [4, 13, 16]. A recent review of 257 children who developed CMS after surgery revealed the distribution of the histopathological diagnoses which found 62.7% of the cases had a medulloblastoma followed by 24.9% had astrocytoma, 11.2% had ependymoma [11]. Similar distribution of medulloblastoma (64%) was also reported in another review followed by a low grade astrocytoma in 36% of cases [10], pineal tumor [7].

CONCLUSION

CMS after surgery is a challenge for the clinicians as well as the patients. The knowledge of this helps in early detection and intervention. Multidisciplinary approach involving psychiatrist, speech- language therapist, physiotherapist and neurologist will bring in better outcome in these cases of CMS. To the authors' best knowledge this is the first reported case in Bangladesh which would help the clinicians to understand and deal with the syndrome.

REFERENCES

1. Lee, S., Na, Y. H., Im Moon, H., Tae, W. S., & Pyun, S. B. (2017). Neuroanatomical mechanism of cerebellar mutism after stroke. *Annals of rehabilitation medicine*, 41(6), 1076.
2. Starowicz-Filip, A., Chrobak, A. A., Moskała, M., Krzyżewski, R. M., Kwinta, B., Kwiatkowski, S., & Przewoźnik, D. (2017). The role of the cerebellum in the regulation of language functions. *Psychiatria Polska*, 51(4), 661-671.
3. Wibroe, M., Cappelen, J., Castor, C., Clausen, N., Grillner, P., Gudrunardottir, T., & Karpainen, A. (2017). Cerebellar mutism syndrome in children with brain tumours of the posterior fossa. *BMC cancer*, 17(1), 1-7.
4. Wells, E. M., Khademan, Z. P., Walsh, K. S., Vezina, G., Sposto, R., Keating, R. F., & Packer, R. J. (2010). Postoperative cerebellar mutism syndrome following treatment of medulloblastoma: neuroradiographic features and origin. *Journal of Neurosurgery: Pediatrics*, 5(4), 329-334.
5. Şahin, H., & Şengül, G. (2014). Cerebellar Mutism.
6. Pitsika, M., & Tsitouras, V. (2013). Cerebellar mutism: a review. *Journal of Neurosurgery: Pediatrics*, 12(6), 604-614.
7. Roka, Y. B., Shrestha, M., Puri, P. R., & Aryal, S. (2011). Cerebellar mutism after pineal tumour

- excision: a case report. *Journal of Nepal Paediatric Society*, 31(2), 124-126.
8. Gudrunardottir, T., Sehested, A., Juhler, M., & Schmiegelow, K. (2011). Cerebellar mutism. *Child's Nervous System*, 27(3), 355-363.
 9. Yildiz, O., Kabatas, S., Yilmaz, C., Altinors, N., & Agaoglu, B. (2010). Cerebellar mutism syndrome and its relation to cerebellar cognitive and affective function: Review of the literature. *Annals of Indian Academy of neurology*, 13(1), 23.
 10. Ça, Ç., Tümörleri, A. Ç., Sonras, C., & Mutizm, S. (2008). Cerebellar mutism following posterior fossa tumor resection in children. *Turkish neurosurgery*, 18(1), 89-94.
 11. De Witte, E., Wilssens, I., De Surgeloose, D., Dua, G., Moens, M., Verhoeven, J., & Mariën, P. (2017). Apraxia of speech and cerebellar mutism syndrome: a case report. *Cerebellum & ataxias*, 4(1), 2.
 12. Sherman, J. H., Sheehan, J. P., Elias, W. J., & Jane Sr, J. A. (2005). Cerebellar mutism in adults after posterior fossa surgery: a report of 2 cases. *Surgical neurology*, 63(5), 476-479.
 13. Wells, E. M., Walsh, K. S., Khademian, Z. P., Keating, R. F., & Packer, R. J. (2008). The cerebellar mutism syndrome and its relation to cerebellar cognitive function and the cerebellar cognitive affective disorder. *Developmental disabilities research reviews*, 14(3), 221-228.
 14. Catsman-Berrevoets, C. E. (2017). Cerebellar mutism syndrome: cause and rehabilitation. *Current Opinion in Neurology*, 30(2), 133-139.
 15. Koh, S., Turkel, S. B., & Baram, T. Z. (1997). Cerebellar mutism in children: report of six cases and potential mechanisms. *Pediatric neurology*, 16(3), 218-219.
 16. Ozgur, B. M., Berberian, J., Aryan, H. E., Meltzer, H. S., & Levy, M. L. (2006). The pathophysiologic mechanism of cerebellar mutism. *Surgical neurology*, 66(1), 18-25.