



Case Report: Cerebellar Stroke with Acute Vestibular Syndrome

Dr. Shreya N. Jani^{1*}, Dr. Neha R. Gulati¹

¹PharmD, Department of Pharmacy, Sumandeep Vidyapeeth Deemed to be University, Vadodara, Gujarat, India

*Corresponding Author

Dr. Shreya N. Jani
PharmD, Department of
Pharmacy, Sumandeep
Vidyapeeth Deemed to be
University, Vadodara, Gujarat,
India

Article History

Received: 17.07.2023
Accepted: 22.08.2023
Published: 04.09.2023

Abstract: The posterior circulation accounts for around 20% of cerebral ischemic strokes. According to estimates, 20% of these individuals appear with solitary vertigo. This symptom is incorrectly classified as peripheral vestibular in roughly one-sixth to one-third of these patients [1]. As a result, therapeutic and secondary preventive treatment is deferred from these missing stroke patients, potentially resulting in avoidable morbidity and mortality. Based on a careful evaluation of the literature, we suggest a diagnostic method for clinical differentiating of individuals with acute vestibular syndrome [2]. A stroke involving the inferior cerebellum must be recognized because it can cause cerebellar enlargement, which can lead to brain stem compression and death unless surgery is performed [1]. We report a case of 45-year-old female who had vertigo for 4-5 months and it is not associated with vomiting and posture or climate change, imbalance while walking for 6 months. She is known case of diabetes for 2 years with ongoing Antidiabetic treatment. Evaluating a central origin vertigo or dizziness is the main consequence here.

Keywords: Acute Vestibular Syndrome, Cerebellar stroke, Vertigo, Head Impulse-Nystagmus-Test of Skew.

Copyright © 2023 The Author(s): This is an open-access article distributed under the terms of the Creative Commons Attribution 4.0 International License (CC BY-NC 4.0) which permits unrestricted use, distribution, and reproduction in any medium for non-commercial use provided the original author and source are credited.

INTRODUCTION

Acute vestibular syndrome is defined as sudden-onset, continuous vertigo lasting longer than 24 hours with associated nausea and vomiting, all of which are worsened with head movement. Acute vestibular syndrome is triggered by a range of central and peripheral causes, the most prevalent of which are vestibular neuritis and acute stroke (posterior circulation) [1]. Early neuroimaging is less sensitive and specific than a clinical strategy concentrating on time, related history, and ocular motor findings, which can increase diagnosis accuracy. Because of the same neurovascular supply, both peripheral and central vestibular diseases can display overlapping symptoms such as vertical skew, nystagmus, aberrant vestibular ocular reflex, hearing loss, and gait instability, which were formerly regarded either peripheral or central. Although acute vestibular syndrome is usually

harmless, stroke should be examined in everyone who has it since it can be a sign of a stroke or an imminent cerebellar herniation. Because there is little evidence pharmaceutical use, the treatment focuses on physical therapy [3]. The acute vestibular syndrome is caused by a unilateral damage to either peripheral or central vestibular structures severe vertigo, vomiting and nausea and also symptoms like Nystagmus and postural instability. In a healthy person these symptoms develop over days, usually caused by a viral vestibular neuritis but it can also be caused by when hearing loss is severe which is referred to as vestibular neuronitis [5]. To distinguish between peripheral and central causes of acute vestibular syndrome, several findings on clinical examination and results of particular tests have been used. However, Infarction and Haemorrhage in the inferior cerebellum can mimic vestibular neuritis. For most vestibular disorders

Citation: Shreya N. Jani & Neha R. Gulati (2023). Case Report: Cerebellar Stroke with Acute Vestibular Syndrome, Glob Acad J Pharm Drug Res; Vol-5, Iss-5 pp- 52-54.

drugs which are been given are vestibular suppressants like benzodiazepines, diazepam, lorazepam, alprazolam, clonazepam, etc. Other than that, some antimigraine and antiemetics and anticholinergics are mostly used [6]. Pathophysiology of Acute Vestibular Syndrome includes certain points. It is a term used to describe new onset severe dizziness, vertigo or imbalance as

well as Nystagmus or unsteadiness on examination. Acute vestibular syndrome is most commonly manifested by acute unilateral vestibulopathy caused by vestibular neuritis. Stroke is also a major worry in acute vestibular syndrome sufferers. The majority of other peripheral vestibular diseases manifest themselves as episodic or persistent symptoms [2].

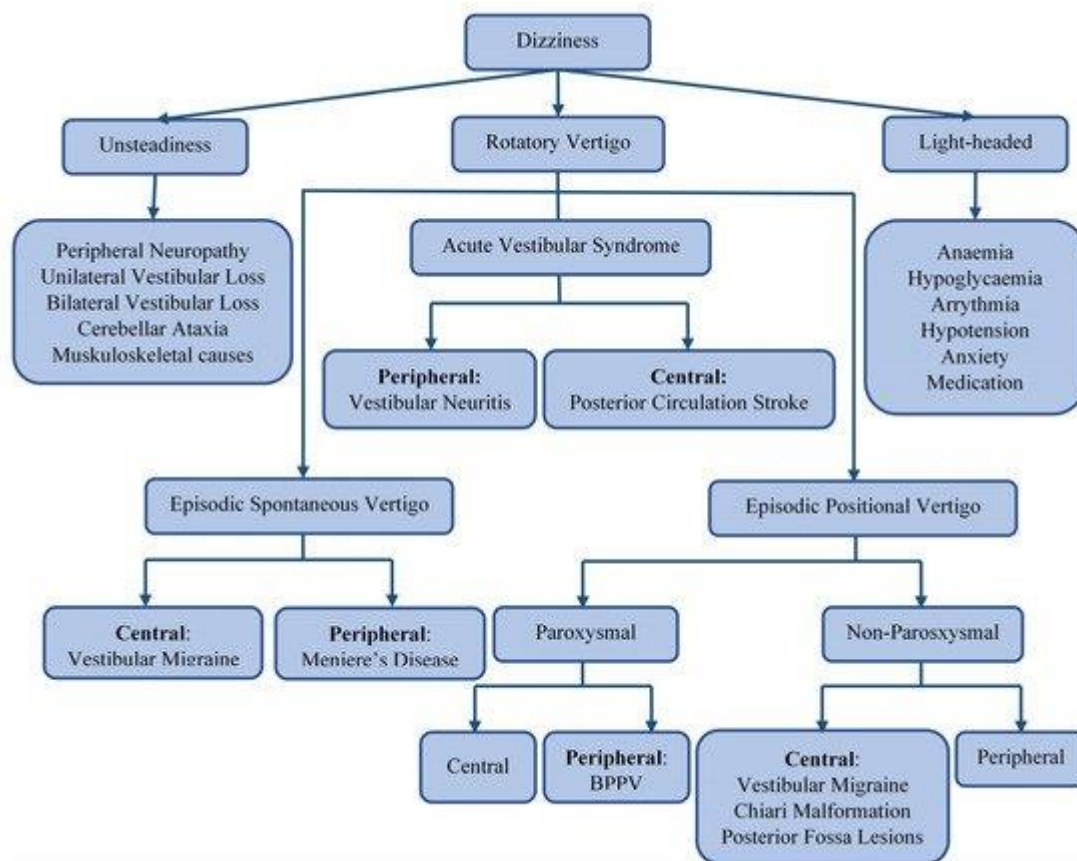


Figure 1: The differential diagnosis of dizziness [8]

CASE REPORT

A 45 years old female patient was admitted to multispeciality hospital with the complaints of dizziness and vertigo for 4-5 months and it is not associated with vomiting and posture or climate change, imbalance while walking for 6 months which was insidious onset. Asymmetrical and gradually progressive. Other than that, no other signs and symptoms were observed. She is known case of diabetes for 2 years with ongoing Antidiabetic treatment of Human Actrapid insulin of 12 U three times a day and insulin Glargine at night once of 12 U subcutaneously. On Examination Patient's Blood Pressure, Pulse, Temperature was normal. Patient was fairly asymptomatic 6 months back, then she started complaining of vertigo, heaviness of head, and Generalised weakness. There is no focal neurological deficit, hearing loss, and the tone of all four limbs is also normal. Rotatory nystagmus was present. The Romberg's sign is positive. Her

personal history shows Mixed diet, normal sleep pattern, and good appetite. On the diagnosis of the root cause of Acute vestibular syndrome she was admitted in the Intensive care unit and provided with Inj. MPS (1gm) IV 24hrly, Inj. 100ml 0.9% NS with 5amp optineuron IV 8 hrly for 90 mins. Inj. Human Actrapid insulin of 12 U three times a day and Inj. Insulin Glargine at night once of 12 U subcutaneously. Tablet Betahistine (16mg) was given three times a day and tablet Prothiaden (25 mg) once a day at night time. Betahistine is a Histamine agonist and it helps in treating vertigo or dizziness. Prothiaden mainly contains dosulepin which is a tricyclic antidepressant, and it mainly act as vestibular suppressants and can also be useful in vertigo. She was advised to carry out Magnetic Resonance imaging of brain. It shows cerebellar tonsillar ectopia. And major dural sinuses shows expected flow void. All the other required laboratory data was found to be normal. The Dix-Hallpike test

was also done in past and it showed benign paroxysmal positional vertigo. And it was treated with Epley maneuver. After evaluating all the necessary tests and reports it was suggested that the patient had Acute Vestibular Syndrome. All other necessary evaluating factors and lifestyle modifications were made understood to the patient.

DISCUSSION

The exclusion of common medical reasons of dizziness is required for the diagnosis of acute vestibular syndrome. The next step is to discover the underlying disease by distinguishing between the two most prevalent causes of acute vestibular syndrome: central and peripheral vestibular abnormalities. Ischemic stroke affecting the cerebellar arteries is the most common cause of central vestibular dysfunction. Inflammation is thought to be the primary cause of peripheral vestibular diseases, yet ischemia of the peripheral vestibular apparatus may be overlooked. Strokes are unlikely to be missed if a full neurologic examination is combined with the Head Impulse Test, Nystagmus, Test of Skew with Plus referring to hearing loss assessment. According to evidence, over two-thirds of stroke patients lack focal neurologic indications that would be obvious to a nonneurologist (and one-third lack signs that would be readily apparent to a neurologist). Vestibular physical therapy aids in the rehabilitation of nearly all acute vestibular diseases [7].

CONCLUSION

Acute dizziness lasting more than a day is a typical occurrence in emergency, and the causes can be fatal. The difference between vestibular neuritis and ischemic stroke is the most important differential diagnostic. Warning for stroke include a history of repeated transitory prodromal episodes of dizziness over months; auditory symptoms; and headache, neck pain, or trauma, albeit physical examination is more helpful than history-taking if acute vestibular syndrome is detected [4]. A bedside oculomotor examination, Head Impulse-Nystagmus-Test of Skew is performed on these patients [7]. Most of individuals with an inferior cerebellar infarction on the other hand do not develop

brainstem compression and make a full recovery. It's possible that their problem gets misdiagnosed as a peripheral vestibular lesion. In order to treat acute vestibular syndrome, it is also vital to recognize it and figure out what's causing it which can help to reduce the chances of a repeat stroke [4].

ACKNOWLEDGEMENT

The authors are sincerely thankful to all the members of Department of Pharmacy, Sumandeep Vidyapeeth Deemed to be University (SVDU) for their support.

CONFLICT OF INTEREST

The authors declare no conflict of interest.

REFERENCES

1. Thabet, E. (2008). Evaluation of patients with acute vestibular syndrome. *Eur Arch otorhinolaryngol*, 265, 341-349.
2. Kerber, K. A. (2020). Acute vestibular syndrome. *Semin Neurol*, 40(01), 059-066.
3. Tarnutzer, A. A., Berkowitz, A. L., Robinson, K. A., Hsieh, Y. H., ... & Newman-Toker, D. E. (2011). Does my dizzy patient have stroke? A systemic review of bedside diagnosis in acute vestibular syndrome. *CMAJ*, 183(9), E571-E592.
4. Ljunggren, M., Persson, J., & Salzer, J. (2018). Dizziness and the acute vestibular syndrome at the emergency department: a population-based descriptive study. *European Neurology*, 79(1-2), 5-12.
5. Hotson, J. R., & Balohn, R. W. (1998). Acute vestibular syndrome. *N Engl J Med*, 339, 680-685.
6. Venhovens, J., Meulstee, J., & Verhagen, W. I. M. (2016). Acute vestibular syndrome: a critical review and diagnostic algorithm concerning the clinical differentiation of peripheral versus central aetiologies in the emergency department. *Journal of neurology*, 263, 2151-2157.
7. Kattah, J. C. (2018). Use of HINTS in the acute vestibular syndrome an overview. *Stroke and vascular neurology*, 000160.
8. Kabade, V., Hooda, R., Raj, C., Awan, Z., Young, A. S., Welgampola, M. S., & Prasad, M. (2021). Machine learning techniques for differential diagnosis of vertigo and dizziness: a review. *Sensors*, 21(22), 7565.